

ORIGINAL PAPER

Aspects of oral morphology as decision factors in mini-implant supported overdenture

ELENA PREOTEASA¹⁾, MARINA MELEȘCANU-IMRE¹⁾,
CRISTINA TEODORA PREOTEASA²⁾, MIHAELA MARIN¹⁾, HENRIETTE LERNER³⁾

¹⁾Department of Prosthodontics

²⁾Department of Oral Diagnosis and Ergonomics

"Carol Davila" University of Medicine and Pharmacy of Bucharest, Romania

³⁾Private practice, Baden Baden, Germany

Abstract

Aim: Evaluation of some morphological oral aspects perceived as decision factors in complete edentulism treatment by mini-implants overdenture. **Patients, Material and Methods:** An observational study was conducted on a sample of 24 patients (average age of 61 years), through clinical and imagistic methods. The variables taken into consideration were: age, gender, alveolar mucosa status, bone offer, mini-implants characteristics, insertion torque and loading type. **Results:** 117 mini-implants were applied, 59% to the lower jaw and 41% to the upper jaw. On average, there were inserted 5.33 implants to maxilla and 4.6 to mandible. Fifty-seven percent of implants were applied in the interforaminal area. The implants used had 10 mm (28.2%) and 13 mm (71.8%). In only 41% patients, the ridge width was higher than 5 mm (value necessary for conventional implant application). Diameters of implant used were: 1.8 mm (2.56%), 2.1 mm (25.64%) and 2.4 mm (71.8%). Smaller diameters were used in mandible. Only in 16.67% of patients was possible the transmucosal insertion. Bone density was D2 and D3 for men, and D3 and D4 for women. Immediate loading was achieved in 20.5% patients. **Conclusions:** Mini-implant supported overdenture can be an alternative to conventional denture and conventional implant overdenture. Its advantages derives from implants' characteristics (smaller diameter, variable length, O-ring retention system), which adapts better to the particular edentulous conditions. Insertion technique implies less surgical trauma. Choosing implants' size, number, topography, and the loading method have a great variety, depending on anatomical feature (bone offer, mucosa and relationship with the nearby anatomical structures), functional features and patients' wishes.

Keywords: edentulous, oral morphology, mini implants, complete overdenture.

☞ Introduction

Within dental care field, complete edentulism is a clinical aspect with a rather large prevalence, perceived as a main feature in the elderly persons. The demographic changes in the current context are characterized by the appearance of new particular issues that involve the general and local status. There can be observed an increased life expectancy especially in the developed nations. Moreover, general medicine and dentistry have made significant progress, both scientifically and improving quality of health services. These led to an increase in patients' age at edentulism installation, aspect that explains the more difficult adaptation of the patients to complete dentures. Generally, there can be seen an increased degree of treatment difficulty within edentulous patients, in correlation with the appearance of new treatment possibilities [1, 2].

In terms of frequency, the first therapeutically option in the complete edentulism is represented by conventional dentures. But, in a large number of cases this therapeutic option does not satisfy the patients' expectations, a number of complains being found out, primarily related to functionality and adaptation. The implant supported overdenture brings considerable benefits,

including the increase of denture stability, functional efficiency, comfort and quality of life. For this reason, not in a few cases, this treatment option has become elective. The main difficulties identified when the treatment plan includes implant application are correlated with the inadequate jaw morphology, due to the important bone resorption phenomena that occurs during edentulism evolution, and also with the poor bone quality, due to osteoporosis [3, 4]. Most times, surgical interventions are needed (bone addition, sinus lift, etc.), which are harder to accept by elderly patients, frequently with affected general status [1]. Other disadvantages are related to longer duration of treatment and higher costs.

In cases where jaw morphology does not allow the conventional implant application without helpful surgical interventions, using small-diameter implants, also known as mini-dental implants (MDI) can be, most often, a treatment alternative. Among benefits are: the application method is easier and has much less intra-operative trauma, in terms of avoiding other surgeries technique with their associated risks, the possibility to be loaded immediately, a shorter recovery period and lower cost [5].

Using mini-implants supported overdentures as a

definitive treatment of edentulous is rather recent [6, 7]. In the literature there can be seen a growing interest in this aspect. Positive signals are related to subsequent benefits of using MDI and registered good results. Griffiths TM *et al.* conclude that mini implants are relatively affordable and patient's satisfaction is excellent [8]. Balkin BE *et al.* showed osseointegration at a microscopic level of immediately loaded MDI [9]. Froum SJ *et al.*, in the study regarding the torsion force during removal, attests the integration of immediately loaded small diameter implants. He also found that the bone-implant contact percentage is comparable to that of conventional implants, suggesting that can be used as final prosthetic treatment [10]. However, MDI are relatively recently used as means for increasing retention and stability of mandibular denture. That is why in the literature there can be found a limited number of longitudinal studies on this theme. Morneburg TR and Pröschel PA, in a six years study, report a success rate of 95.5%, while LaBarre EE *et al.* were reporting in the same period a rate of 92.6%. The highest failure rate was found at about six months after insertion, during the osseointegration period [11, 12].

The aim of our research was to evaluate and record some morphological features that can be important decision factors in planning mini-implant supported overdenture. These may influence the choosing of implant type (conventional or MDI), its parameters and the practical attitudes during treatment. All these are analyzed in the environment given by the particularities found in the complete edentulous state, frequently unfavorable to implant supported overdenture.

Looking ahead, we plan to do a study on a larger number of patients, in order to achieve a higher validity of results. Also we want to complete our findings with some regarding the prognosis of this treatment alternative, compared with other options like conventional implant supported overdenture, teeth supported overdenture and conventional complete denture.

☒ Patients, Material and Methods

An observational clinical study was conducted on a sample of 24 patients with average age of 61 years (52–72 years) and 1:1 women to men ratio.

The main criterion in subject selection was the presence of complete edentulism condition, untreated or previously treated, but with an unsatisfactory perception concerning the denture. In the sample were included only the patients who accepted as treatment solution the overdenture anchored on mini implants. There were excluded patients with severe systemic diseases (diabetes mellitus, uncontrolled hypertension grade III, etc.) because the risk associated with the surgery procedure of implants insertion was considered to be significant and the prognosis could have been negatively influenced by it. After the sample establishment it followed a phase in which patients were informed and a written consent was obtained.

The mini-implants used were those supplied by IMTEC, available in four lengths variants (10 mm, 13 mm, 15 mm and 18 mm), three diameters (1.8 mm,

2.1 mm and 2.4 mm) with collar and O-ring as anchoring system.

In order to achieve the target objectives, we recorded the data presented in Table 1, in which it is also present the obtaining method for each one.

Table 1 – Registered parameters needed to accomplish the study

Data registered for each patient	Evaluation method
Age, gender	History
Status of alveolar mucosa (presence of inflammatory phenomena, thickness, resilience)	Clinical examination
Evaluation of bone offer, quantitative (height and width) and qualitative (bone density according to Misch classification – Figure 1)	Clinical examination with periodontal probe and bone compass (Figure 2), cast, panoramic and computerized tomography analysis
Relationship with the nearby anatomical structures	Panoramic (Figure 3) and computerized tomography analysis
Torque at insertion point	Implant torque wrench (Figure 4)
Delayed or immediate loading of implants	
Implant length and diameter	

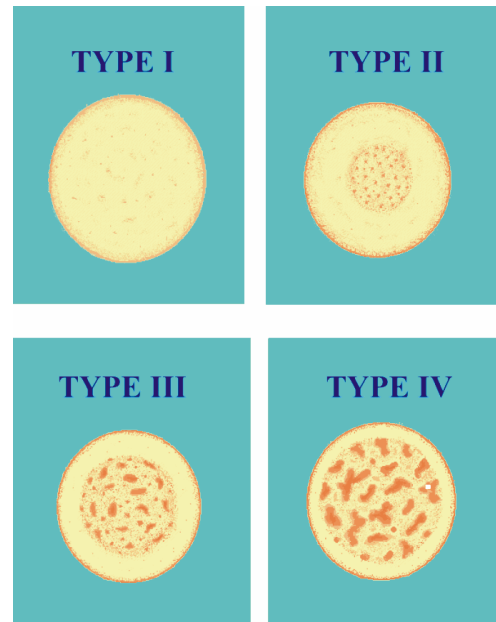


Figure 1 – Bone density according to Misch.

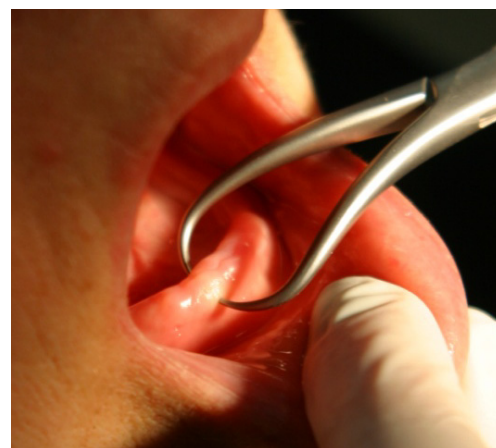


Figure 2 – Assessing the ridge's width with the bone compass.

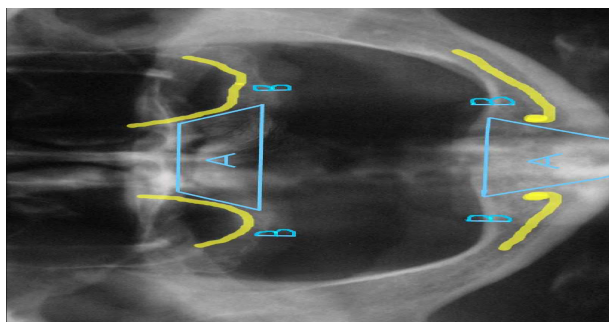


Figure 3 – Assessing the relationship with the nearby anatomical structures by orthopantomography analysis.



Figure 4 – Implant torque wrench.

Data collection was achieved in two stages. In the first phase the case analysis, diagnosis assessment and treatment plan were done. Data was obtained through discussion with the patient (history), clinical investigations, imagistic methods (panoramic and computerized tomography) and cast analysis. The second stage was the one where the treatment itself was realized, namely the insertion and loading of implants. The value of torque during implant application was recorded.

Throughout the entire study, the computed tomography did not contribute to diagnostic assessment. The information was used as auxiliary, in order to verify the data obtained by clinical and panoramic analysis. Our purpose was to see if, in cases with MDI application, it could be excluded from the initial file of the patient.

Results

Correlations between implants' number and topography in relation to patient's gender

In our study group, the ratio between men and women was 1:1, and in terms of number of inserted implants the women outnumbered men by three implants.

To all 24 patients there were applied a total of 117 MDI, between four and six implants by jaw (average value: 4.87). A greater number of implants were applied to the lower jaw (n=15 patients, 62.5%) compared to the upper jaw (n=9 patients, 37.5%). Analyzing the total number of inserted implants, the number was greater in the mandible (n=69, 59%) than in the maxilla (n=48, 41%). However, analyzing the average number of implants inserted to one jaw, in the maxilla (5.33) the number was higher than the one in the mandible (4.6). Regarding the topography, differences were found between anterior and posterior sectors (Figure 5). The largest number of implants was applied on the interforaminal area of the lower jaw (n=57, 48.73%).

Differences were found on the topography of implants in relation to patients' gender. At women, there were inserted a total number of 60 implants. Out of

these, most have been applied in the anterior part of the mandible (n=33, 55%) and the fewest in the posterior maxilla (n=3, 5%). At men, there were inserted a number of 57 implants. For them an equal implant percentage (n=24, 42%) were inserted in the anterior part of the upper and lower jaw. The number of implants placed was the largest in women to the anterior part of the lower jaw and no implant was applied in men at the posterior mandible.

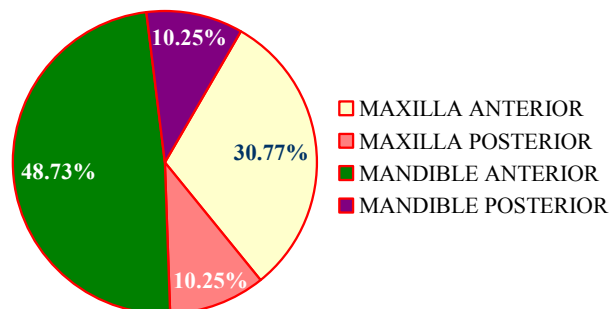


Figure 5 – Topographical distribution of inserted implants.

Correlations between alveolar mucosa status and treatment plan

In all cases, the attached mucosa was considered to be healthy, with no sign of congestion present. Regarding the thickness and resiliency of mucosa, various aspects were found. In 16.67% (n=4) patients flapless transmucosal implant placement was done. In the other cases (83.33%, n=20 patients), due to the rich sub mucous layer, it was necessary to make an incision and to create the flap before implant insertion. The last version presented the advantage of a greater certainty concerning the implant direction during insertion, but is characterized by increased intraoperative trauma.

Correlations between maxillaries bones offer (quantitative and qualitative), implants features and insertion torque

The bone features in terms of quantity (bone height and ridge width) and quality (bone density) were the final decision elements in choosing the implants type and number, and influenced the therapeutically act (torque value).

Correlations between bone height and implant length, reported to various topographical areas

The bone height presented quite significant variations (12–25 mm). Its value was directly related with the adjacent anatomical structures relationship (maxillary sinus, nasal fosse, mandibular canal).

The most common implant lengths used was 13 mm (n=84, 71.8%), and the rest had 10mm (n=33, 28.2%). In areas where have been applied 10mm implants, the bone presented heights between 12–14 mm (average value of 12.63 mm). In areas where the implants applied had 13 mm length, the bone presented values of 14–25 mm (average value of 18.14 mm). The highest value for bone height, meaning the best conditions for implants insertion, was found in the anterior lower jaw (Table 2).

Table 2 – Correlations between bone height and implant length

	Frontal maxillary		Side maxillary		Frontal lower jaw		Side lower jaw	
	Extreme values	Average values	Extreme values	Average values	Extreme values	Average values	Extreme values	Average values
Bone's height [mm]	13–16	14.58	12–13	12.5	14–25	19.63	12–13	12.25
Implant's length [mm]	10.13	12.25	10	10	13	13	10	10

Correlations between ridge width and implant diameter, reported to various topographical areas

The measured value of the ridge width was 3–7 mm. From this point of view, the maxillary values found were higher and more constant, translated as a positive aspect for implants insertion in terms of their diameter. On the other hand, in the lower jaw there was frequently identified a poorly ridge width, which means in a number of cases an indication for MDI.

Considering that conventional implants require a ridge width larger than 5 mm, there were examined the group characteristics of the sample regarding this issue. 59% of the areas where there were MDI inserted, had a ridge width lower than 5 mm, and only 41% higher.

The implants diameters used were the following: 1.8 mm (2.56% of implants), 2.1 mm (25.64%) and 2.4 mm (71.8%). The 1.8 mm diameter was chosen where the ridge presented a width that was lower than 4 mm (average of 3 mm), the 2.1 mm diameter where the ridge width was about 4–6 mm (average of 4.8 mm) and the 2.4 mm diameter where the ridge width was about 4–7 mm (average of 5.5 mm). In both anterior and posterior maxillary area, there were used only 2.4 mm diameter implants. In the anterior lower jaw there were used 1.8 mm diameter implants (5.26% of mandible implants), 2.1 mm (42.10%) and 2.4 mm (52.64%), and in the posterior area implants with 2.1 mm (50%) and 2.4 mm (50%) diameters (Table 3).

Table 3 – The correlation between ridge width and implants diameter

	Frontal maxillary		Side maxillary		Frontal lower jaw		Side lower jaw	
	Extreme values	Average values	Extreme values	Average values	Extreme values	Average values	Extreme values	Average values
Ridge width [mm]	5–7	5.75	5–6	5.5	3–7	4.95	4–6	5
Implant diameter [mm]	2.4	2.4	2.4	2.4	1.8, 2.1, 2.4	2.14	2.1, 2.4	2.25

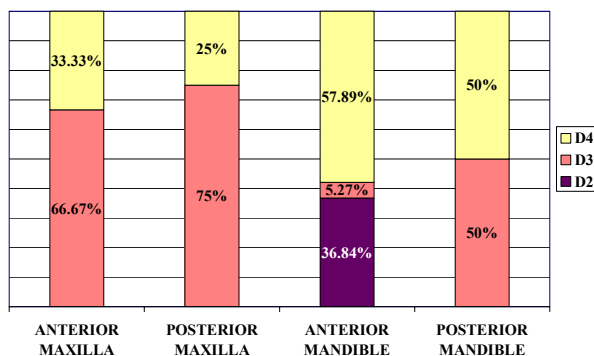
Bone density issues

Correlations between bone density and patients' gender

The D1 density was not identified in any case. D2 density was found to be present only in males. D3 density was present both in women and men. D4 density was present only at women. In conclusion, in our study, men presented more favorable conditions for implants insertion.

Bone density in relation to topographical area

The bone density presented variable values according to the examined topographical area (Figure 6). D3 and D4 densities were present in all the regions. D2 density was found only in the anterior mandibular area. Surprisingly, D4 bone density, the most unfavorable for implant insertion, was present in a higher percentage in the lower jaw region, mainly in the anterior part, but also on the lateral sector.

**Figure 6 – Topographical distribution of bone density.**

Correlations between bone density and torque at implant insertion

Torque during insertion presented different values, being mainly related to bone density in that respective area. Where density was assessed as having D2 values, the torque was over 40 Ncm. In D3 density areas, the torque value was 30 Ncm or 35 Ncm (average value 32.14 Ncm). At D4 density, the torque had values below 30 Ncm (respectively 10, 15, 20, 25 Ncm, with average value of 21.11 Ncm).

Correlations between density and the implants loading type

Immediate loading was performed in 20.5% (n=24) of implants, in the rest of the cases being preferred the delayed implant loading. All immediately loaded implants were inserted in the anterior lower jaw area. Within the group of immediately loaded implants, 87.5% (n=21) were inserted into a bone presenting D2 density, and 12.5% (n=3) in D3 bone density. Delayed loaded implants were inserted in D3 (33.33%, n=39) and D4 (66.67%, n=54) density bones. Immediate loading was achieved by using the previously made complete dentures (by setting the matrix in the base). When this situation was used, the torque presented values higher than 35 Ncm and was found particularly in men, in lower jaw, with D2 bone density. The delayed implant loading (at three months after the implant insertion) was done in women, when torque presented values below 35 Ncm, with a D3 or D4 bone density. Age did not directly influence the loading process, except for physiological features in women with impaired bone density in the presence of osteoporosis.

Discussion

Using mini-implants supported overdenture as a definitive method for treating the edentulous is relatively recent and this is why there are not so many articles on the topic.

This therapeutic alternative is seen by a large group of authors as indicated especially for the mandibular complete edentulism. The place where MDI are indicated to be applied is the interforaminal area, in a number of minimum 4 [12, 13]. Our results are in agreement with this opinion. Treatment with MDI supported overdenture was more frequently done in the mandible (the decision was taken according to the patient's needs and the prosthetic requirements identified by the specialist). The largest number of implants was applied in the interforaminal area.

Regarding the indicated number of implants that should be used, specialists' opinions are very different. Some say it is sufficient one or two, others say that minimum 4 mini implants in the lower jaw and 6 to the maxillary are needed [6, 13, 14]. We placed between 4 and 6 MDI on a jaw, an average of 5.33 in the maxilla and 4.6 in the mandible (Figures 7 and 8).

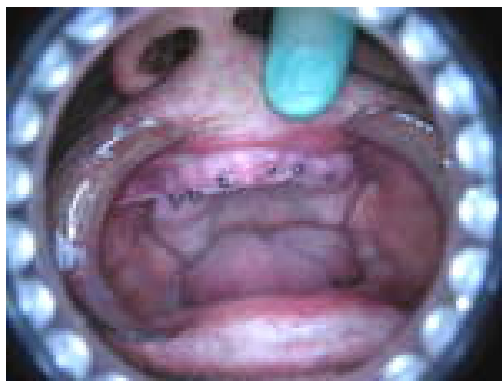


Figure 7 – Six MDI applied in the maxilla.

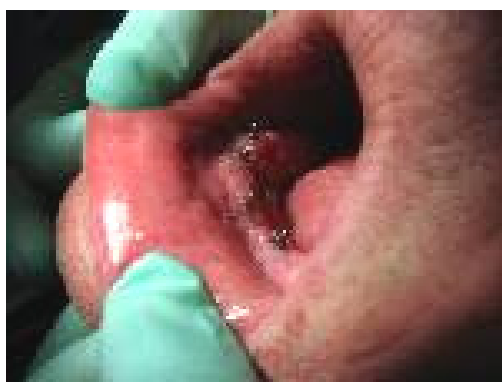

Figure 8 – Four MDI applied in the mandible.

The areas where the implants were applied had a bone height of at least 12 mm. This value is a match with the data from other studies (a height smaller than 11 mm is considered exclusion criteria).

Surgical technique may be performed with or without incision of the soft tissue. The last one is preferred when possible, due to the smaller surgical trauma [13]. This may represent an important benefit of this technique, if we consider the usually poor general status of these patients.

One of the main advantages of these implants, commonly identified in literature, is that they can be placed in areas where the ridge width is very small and where, unless helpful surgery intervention are performed, conventional implants can not be placed. The necessary ridge width in order to apply a conventional implant must be bigger than 5 mm. MDI may be inserted also where the ridge width presents values of 3–4 mm [6]. In our study, only in 41% of inserted implants could have been replaced with the conventional ones. In the rest of the cases, the morphological conditions were inadequate for this technique. Implants with a 1.8 mm and 2.1 mm diameter are recommended to be inserted into a ridge width of a 3–4 mm [6]. We used 1.8 mm implants where the ridge width presented a value of 3 mm and 2.1 mm diameter implants into a 4.8 mm ridge width.

Regarding the bone density, an important factor in implant treatment planning, many studies highlight the implications of menopause on the bone structure. This illness is correlated with a decreased bone density and it is usually found in older woman [3–5]. In our study, female patients had D3 (10%) and D4 bone density (90%), meaning unfavorable condition for implant application. Some authors see D4 bone density as a contraindication factor for implant placement [6, 15].

Usually D3 density is found mostly in the anterior and posterior region of maxilla, situation present also in our study. D4 density is usually seen as typical for posterior maxilla [6, 15]. We found D4 density in all topographical areas, more frequent in the lower jaw compared to the upper jaw. We encountered the D2 bone density only in men, in the anterior region of the mandible, area identified in the literature as specific for this density in elderly. The bone density is correlated with torque during implant insertion. When D2 bone density was identified, torque value was 40–45 Ncm, in D3 bone the torque used was 30–35 Ncm and in D4 a torque lower than 30 Ncm.

Most authors agree that immediate loading of MDI does not raise any problems [13, 14]. Immediate loading is recommended in D1 and D2 densities [6]. We proceeded with the immediate loading in patients with mainly D2, but also D3 bone density. We choose delayed loading where D3 and D4 bone was present.

The full edentulism is frequently associated with elderly persons, who generally have a lower income. In this context, overdenture on mini implants becomes an advantageous treatment solution, being generally perceived as having lower costs [13].

Regarding the use of imagistic methods, we used panoramic X-rays as a diagnostic mean and Computed Tomography only for double-check. By analyzing the methodology of other studies, we saw that usually nothing was mentioned in protocols about using computer tomography. In this context, we consider that MDI supported overdenture is a treatment that, in general, can be done without data from computerized tomography [6, 13].

Conclusions

Mini-dental implant supported overdenture can be in complete edentulous patients a treatment alternative to

both conventional dentures and conventional implant retained overdenture.

The advantages of this type of treatment derives from the characteristics of this type of implant (small diameter, variable length, O-ring retention system), which adapts better to the particular morphological conditions present in full edentulous patients. Also, the implants insertion requires less surgical trauma, this being a beneficial aspect in the context of usually poor general status.

Proceeding and achieving the treatment requires needs careful evaluation through clinical, imagistic and laboratory methods. Frequently there are identified some unfavorable conditions for implant insertion and a high degree of treatment difficulty. These issues (morphological and functional features, related to general health status, age, gender, etc.) must be linked to implants characteristics, in order to decide the particular treatment features, from surgical and prosthetic point of view. The length, diameter, number, topography, loading method of implants can present a large variety, depending on quantitative bone offer (ridge width and bone height), quality (bone density), functional features and patient's wishes.

This type of treatment has a lower cost compared to conventional implant supported overdenture, by the lower cost of mini-implants, and also due to the use, in general, just of the panoramic radiography as imagistic method (computed tomography is an adjuvant method, but not essential in most cases). Also by eliminating some surgical intervention, we eliminate also their costs. On the other hand, the benefits related to an improved stability, better functionality and adaptation are quickly noticed by the patient and increases their level of satisfaction.

Due to the relatively simple technique, less traumatic, but with benefits that are quickly perceived, the mini-implant supported overdenture may be the elective treatment alternative for complete edentulous patients.

References

- [1] PREOTEASA E, BĂNCESCU G, LONESCU E, BĂNCESCU A, DONCIU D, *Epidemiologic aspects of the totally edentulous mouth. (1) General aspects*, Bacteriol Virusol Parazitol Epidemiol, 2004, 49(3-4):115-120.
- [2] PREOTEASA E, LONESCU E, BĂNCESCU G, BĂNCESCU A, PREOTEASA CT, *Epidemiologic aspects of the edentulous mouth (II). General and local features of the totally edentulous mouth*, Bacteriol Virusol Parazitol Epidemiol, 2005, 50(1-2):27-34.
- [3] MELESCANU M, PREOTEASA E, *Mandibular panoramic indexes predictors of skeletal osteoporosis for implant therapy*, Curr Health Sci J, 2009, 35(4):291-296.
- [4] FRIEDLANDER AH, *The physiology, medical management and oral implications of menopause*, J Am Dent Assoc, 2002, 133(1):73-81.
- [5] ROBERTS WE, SIMMONS KE, GARETTO LP, DECASTRO RA, *Bone physiology and metabolism in dental implantology: risk factors for osteoporosis and other metabolic bone diseases*, Implant Dent, 1992, 1(1):11-21.
- [6] LERNER H, *Minimal invasive implantology with small diameter implants*, Implant Pract, 2009, 2(1):30-35.
- [7] ***, IMTEC Corporation official website, retrieved December 13, 2009, <http://www.imtec.com/europe/>.
- [8] GRIFFITTS TM, COLLINS CP, COLLINS PC, *Mini dental implants: an adjunct for retention, stability, and comfort for the edentulous patient*, Oral Surg Oral Med Oral Pathol Oral Radiol Endod, 2005, 100(5):e81-e84.
- [9] BALKIN BE, STEFLIK DE, NAVAL F, *Mini-dental implant insertion with the auto-advance technique for ongoing applications*, J Oral Implantol, 2001, 27(1):32-37.
- [10] FROUM SJ, SIMON H, CHO SC, ELIAN N, ROHRER MD, TARNOW DP, *Histological evaluation of bone-implant contact of immediately loaded transitional implants after 6 to 27 months*, Int J Oral Maxillofac Implants, 2005, 20(1):54-60.
- [11] MORNEBURG TR, PRÖSCHEL PA, *Success rates of micro-implants in edentulous patients with residual ridge resorption*, Int J Oral Maxillofac Implants, 2008, 23(2):270-276.
- [12] LABARRE EE, AHLSTROM RH, NOBLE WH, *Narrow diameter implants for mandibular denture retention*, J Calif Dent Assoc, 2008, 36(4):283-286.
- [13] ORDOÑEZ A, EASTMOND V, *Mini-dental implants – they're here to stay*, Postgraduate Dentist Caribbean, 3(1):7-12.
- [14] SHATKIN TE, SHATKIN S, OPPENHEIMER AJ, *Mini dental implants for the general dentist: a novel technical approach for small-diameter implant placement*, Compendium, 2003, 24:26-34.
- [15] MISCH CE, *Dental implant prosthetics*, 1st edition, Mosby, St. Louis, 2005, 130-141.

Corresponding author

Elena Preoteasa, Professor, PhD, Department of Prosthodontics, "Carol Davila" University of Medicine and Pharmacy, 5 Plevnei Avenue, 050051 Bucharest, Romania; Phone +4021-315 86 49, e-mail: dr_elena_preoteasa@yahoo.com

Received: January 15th, 2010

Accepted: April 20th, 2010