

# Bone Grafts For Implant Dentistry: The Basics

Fay Goldstep, DDS, FACD, FADFE

**T**he implant restoration is an essential everyday treatment to replace missing teeth, advance function and enhance esthetics for patients in the general dental practice. An understanding of implant hardware design and placement for optimum clinical results is common knowledge for the dental practitioner. This is not the case when it comes to the understanding of bone grafting needs and procedures that are the foundations for implant treatment.

This article will address the basic principles for bone grafts in implant dentistry: the rationale, indications, locations, requirements, types, materials, and some guiding consensus on surgical techniques and materials. This will help clarify a somewhat murky new area for the general practitioner

who needs to know more – whether it is to provide guidance to patients, or to increase understanding of the surgical protocols of implant treatment.

## The Rationale for Bone Grafts

Placement of implants requires sufficient bone volume and biologic quality. This is due to the macro design of the implant, which demands certain dimensional properties for long-term success.<sup>1</sup>

Other factors which make bone grafting necessary are:

### GRAFTS FOR IMPLANTS: THE BASICS

RATIONALE

INDICATIONS

REQUIREMENTS

CLASSIFICATION  
BY MATERIAL SOURCE

CLINICAL CONSENSUS

Outline of topics

- The resorption of the edentulous ridge post extraction
- Presence of bony defects due to trauma or infection
- The need to place implants in strategic sites for functional and esthetic success. In esthetic areas, soft tissue requires a bony base since “soft tissue follows hard tissue”<sup>1</sup>

Treatment planning for bone graft placement requires the selection of an appropriate surgical technique and graft material. Poor planning or execution may lead to resorption of the graft material or its failure to integrate. In addition, the lost tissue may be replaced by fibrous tissue rather than functional bone.<sup>2</sup>

Grafts are suitable for a variety of clinical situations.

### Locations/Indications for Bone Grafts in Implant Treatment

Bone graft materials are placed in different locations for various indications:<sup>1</sup>

- In alveolar sockets post extraction
- To refill a local bony defect due to trauma or infection
- To refill a peri-implant defect due to peri-implantitis
- For vertical augmentation of the mandible and maxilla
- For horizontal augmentation of the mandible and maxilla

Following the extraction of a tooth, 40 to 60 percent of the original height and width of the surrounding alveolar bone is expected to be lost; the greatest loss is in the first two years<sup>3</sup> (Fig. 1).

With this loss of hard and soft tissue, conditions are less favourable for the proper axial alignment of the implant for function and esthetics. To minimize alveolar atrophy post extraction, healing procedures termed “socket preservation” or “ridge preservation” have been developed. These procedures involve filling the socket with bone or bone substitute material, with or without a membrane. The objectives of ridge preservations are:<sup>4</sup>

- Filling the socket (wound care)
- Preservation of ridge volume (ridge preservation)
- New bone formation (osteogenesis)

BONE GRAFT CLASSIFICATION BY MATERIAL SOURCE			
TYPE	SOURCE	PROS	CONS
AUTOGRAFT	PATIENT	TRUE OSTEOGENIC LIVING CELLS GROWTH FACTORS NO DISEASE TRANSMISSION GOOD WITH CORTICAL BONE	PAIN INFECTION COMPLEX SURGERY LIMITED SUPPLY
ALLOGRAFT	OTHER HUMAN	OSTEOINDUCTIVE OSTEOCONDUCTIVE EFFECTIVE AS “SHELLS”	RISK OF DISEASE TRANSMISSION
XENOGRAFT	OTHER SPECIES (mostly bovine)	HA: SIMILAR TO HUMAN VOLUME STABILITY	OSTEOCONDUCTIVE ONLY
		COLLAGEN: ACCELERATES BONE FORMATION	
ALLOPLAST	SYNTHETIC	NO RISK OF DISEASE TRANSMISSION	OSTEOCONDUCTIVE ONLY
	HYDROXYAPATITE	RESORBED SLOWLY →PRESERVES VOLUME GOOD GROWTH FACTOR CARRIER	
	TCP	RESORBED QUICKLY →REPLACED BY NEW BONE	
	BIOGLASS	BIOACTIVE →ACCELERATES BONE FORMATION RESORBED QUICKLY →REPLACED BY NEW BONE	

Bone graft classification by material source

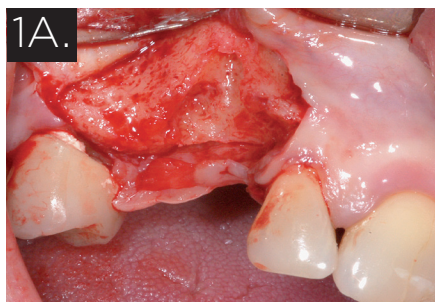Ridge preservation procedures seem to delay bone formation in the early healing phases<sup>5</sup>; however, studies show that procedures are effective with significantly lower ridge atrophy reported than in non-treated groups.<sup>6</sup>

There is always some bone loss after extraction, since the alveolar bundle bone into which the collagen fibres of the periodontium are anchored, is dependent on the presence of a tooth; this bone is always absorbed following tooth loss.<sup>7</sup>

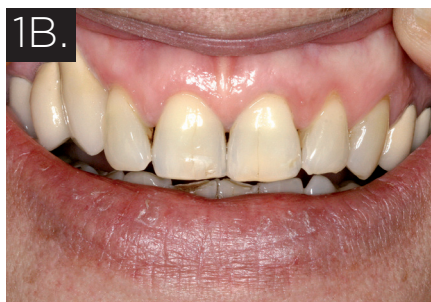**The prime objective of ridge preservation is to diminish or completely eliminate the necessity of more invasive augmentation procedures in the future.**

Techniques are available to effectively and predictably increase the width of the alveolar ridge (horizontal augmentation). Vertical augmentation techniques are not as predictable as those for horizontal augmentation and are subject to more complications.<sup>8</sup>

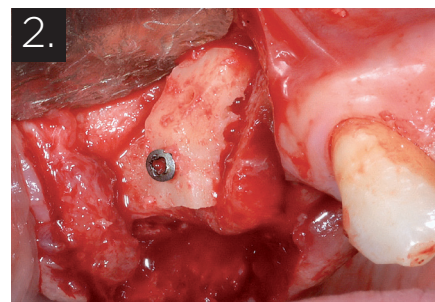
Bone grafts are more likely to succeed when the conditions at the recipient site are favourable and certain requirements are fulfilled.



Following extraction, bone loss can be up to 60 percent of the original height and width of the alveolar ridge.



Poor esthetics can result from implant placement without consideration of post-extraction changes. Courtesy of Dr. M. Leventis, Athens University, Greece.



Placement of an autogenous bone block taken from the chin area. Courtesy of Dr. M. Leventis, Athens University, Greece.

### Requirements for the Ideal Bone Graft

Bone healing and new bone formation after grafting occur through osteogenesis, osteoinduction and osteoconduction:<sup>3</sup>

- **Osteogenic** graft materials supply actual viable osteoblasts themselves
- **Osteoinductive** materials stimulate primitive mesenchymal cells brought in via the blood supply from adjacent bone or periosteum to differentiate into osteoblasts
- **Osteoconductive** materials merely act as a lattice or framework for cell growth, allowing osteoblasts from the wound margin to infiltrate the defect and to migrate across the graft. This brings a population of osteoblasts into the graft site

For the bone graft to be successful:<sup>2</sup>

1. Osteoblasts must be present at the site
2. Blood supply must be sufficient for nourishment
3. The graft must be stabilized during healing
4. The soft tissue must not be under tension

Bone is in a constant process of renewal with formation and resorption. During the first year of life almost 100 percent of the skeleton is replaced, while in adulthood the rate is closer to 10 percent per year.<sup>9</sup> Remodeling enables bone to adapt functionally to changes in loading.

**Osteoblasts** – Only osteoblasts create new bone. For a graft to be successful, the graft matrix must contain or encourage population by osteoblasts. If there is an insufficient number of osteoblasts the graft will fail.<sup>2</sup>

**Blood supply** – Bone grafting is **regeneration** not repair. The term “repair” implies the regaining of lost tissue; **regeneration** is a biologic process where not only is the tissue regained, but also its form and function. This requires a good blood supply to the graft and surrounding tissue. Blood is needed for cell viability and clot formation. The clot serves as the initial matrix where cells migrate and then serves as anchorage for

the osteoblasts.<sup>2</sup>

**Graft stabilization** – Mechanical stresses on the graft during healing can lead to disruption of the fibrin clot. Movement will cause fibrous tissue to fill the defect instead of bone. This is a form of repair and is not true regeneration. Fixation devices like GBR (guided bone regeneration) collagen membranes, titanium mesh and bone screws may be used.<sup>2</sup>

**No tension on the soft tissue** – Bone is the slowest growing tissue. Guided bone regeneration is based on the separation of the grafted site from the surrounding soft tissue. The GBR membrane keeps the faster growing tissues like epithelium, fibrous tissue or gingival connective tissue out of the defect allowing controlled regeneration to occur with vital bone formation.<sup>2</sup> The application of bone graft material into the defect prevents the collapse of the collagen membrane and it acts as a place holder for new regenerating bone and an osteoconductive scaffold for the in growth of blood vessels and osteoblasts.<sup>10</sup>

There are different types of bone grafts available, typically classified by the source of the material used.

### Bone Graft Classification by Material Source

The autogenous graft (where tissue is transferred from one location to another in the same individual) is considered to be the gold standard. It is osteogenic, osteoinductive and osteoconductive.<sup>3</sup> There is biological activity due to vital cells and growth factors. There is also no risk of disease transmission. However there is an increased risk of pain, infection, donor site morbidity, complexity in the surgical procedure, and a limited supply of bone<sup>3</sup> (Fig. 2).

Bone substitute materials (BSM) were developed to counteract the difficulties of autogenous grafts. They can either replace autogenous bone entirely or expand the autogenous graft. Materials need to be effective for procedures both before insertion of the implants (time-delayed procedures) and for



# TestDrive SciCan

Now you can testdrive our handpieces.

## Want to try our handpieces?

All you have to do is choose which product(s) you want to try. We'll take care of the rest.

### TestDrive our

#### **STATIS® Air-driven High-speeds**

Designed without compromise.

#### **SANAO™ Precision Handpieces**

The perfect balance of engineering and ergonomics.

#### **E-STATIS™ Motor Systems**

Compact, powerful, and versatile.

### How it works:

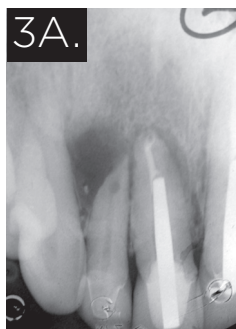- 1 Choose which product(s) you want to TestDrive and enroll online.\*
- 2 TestDrive the product(s) for 7 days.
- 3 Buy the product(s), or, if you do not wish to purchase, simply return to SciCan.

# Enroll Now

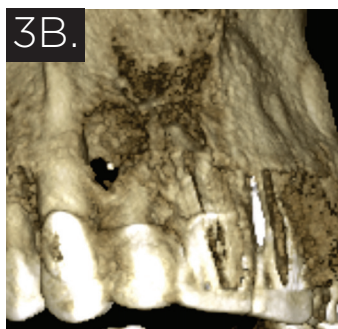at [www.scican.com/testdrive](http://www.scican.com/testdrive)



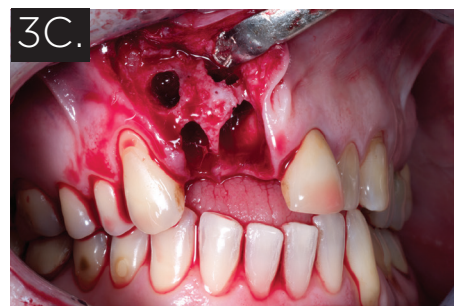→ from page 38



Periapical radiograph showing pathology associated with central and lateral incisors (#11 & #12).



CBCT 3D reconstruction showing pathology in the same case.



Elevation of flap, extraction of teeth, curettage of granulation tissue and maintenance of remaining alveolar bone.

optimization of the recipient site at the time of implant placement (simultaneous procedures).<sup>1</sup>

Grafts are classified as:<sup>11</sup>

**Autograft (autogenous graft):**

Tissue transferred from one location to another within the same individual

**Allograft:**

A graft between genetically dissimilar members of the same species i.e. human tissue

**Xenograft:**

A graft taken from a donor of another species i.e. bovine, porcine etc



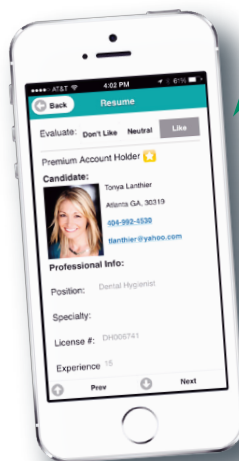
THE PREMIER  
MOBILE & ONLINE DENTAL JOB BOARD & EMPLOYMENT RESOURCE

Use **DATA** to make  
a better hiring decision!

now in



\*Toronto and surrounding metro area



## Post

- Post jobs
- 30-day job posting

## Search

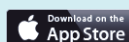- Resumes on web or mobile device
- Profile photos
- Personality tests
- Value assessments
- Skills
- Work culture assessments

## Hire

- Use data to hire a better fit
- View applications anywhere, anytime
- Save time with Candidate Matching\* using our new algorithm

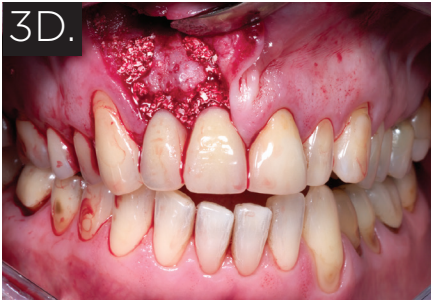Visit [www.DentalPost.net](http://www.DentalPost.net) to learn more!

Connect with us!

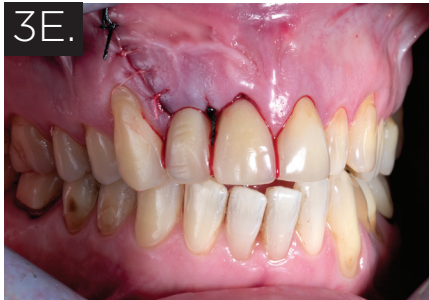

Tonya Lanthier, RDH  
CEO, DentalPost.net

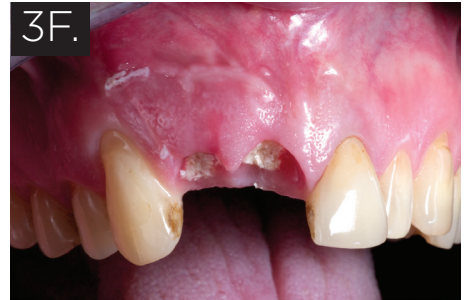



3D. Placement of particulate xenograft (MIS 4BONE™ XBM) to fill bone defect with partial denture in-situ to retain the material.



3E. Tension free suturing with 4-0 black silk sutures.



3F. Labial view at two weeks.

#### *Alloplast:*

Inorganic, synthetic or inert foreign material implanted into tissue

The **autograft** is the patient's own bone. It is chiefly harvested intraorally or from the iliac crest. It is the ideal bone substitute since it contains living cells and human growth

factors. It has greater osteogenic potential than any other bone substitute as well as inherent biocompatibility.<sup>12</sup>

The **allograft** can be derived from cadavers or living donors (tissue harvested from hip replacement surgery). It has natural bone composition and structure. This tissue is osteoinductive as well as osteoconductive but lacks osteogenic properties

**Miele**  
PROFESSIONAL

**Fully compliant.**

**Is your practice compliant with the new CSA Z314.8 standard?**



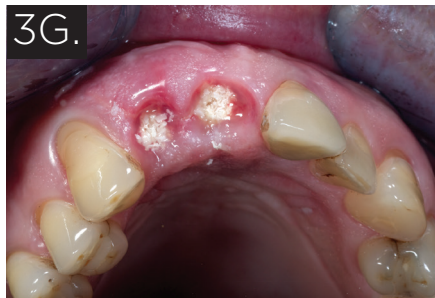
Contact your  
Miele  
infection  
control  
professional

Miele's entire dental product portfolio complies with the most stringent international and national infection control standards and protocols.

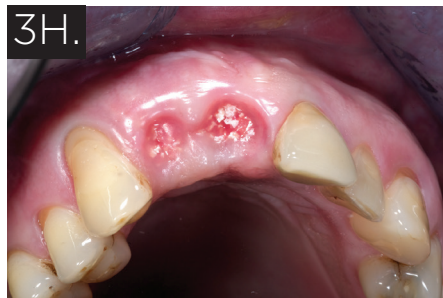
- ISO 15883, CSA Z134.8, all provincial infection control guidelines
- Registered Health Canada Class II Medical Devices

If you plan to automate your instrument reprocessing centre, choose the brand that uses thermal disinfection in every wash to protect your staff from viruses like HIV and Hepatitis.

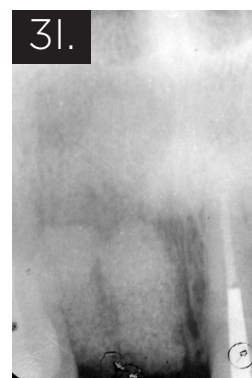Info: 1-888-325-3957 | [www.mieleprofessional.ca](http://www.mieleprofessional.ca)



Incisal view at two weeks showing presence of xenograft granules.



Incisal view at five weeks with partial epithelialization of the extraction sockets.



One month radiograph of grafted sites at #11 & #12.

because of the absence of viable cells.<sup>12</sup>

A controversy exists as to the association of allogenic material and the risk of transmission of infections such as HIV, hepatitis B and C, prions, malignancies, systemic disorders or toxins. Aggressive allograft processing gives it a less intense

immunologic response, but reduces the osteoinductive properties. Frozen allografts induce stronger immune responses than freeze dried allografts, hence they are no longer used.<sup>12</sup>

The donor tissue is cleaned and then undergoes ultrasonics to remove blood and tissue components and to eliminate fat

Season's  
Greetings

## Dental Emergency Service

*helping dentists help  
their patients since 1979*

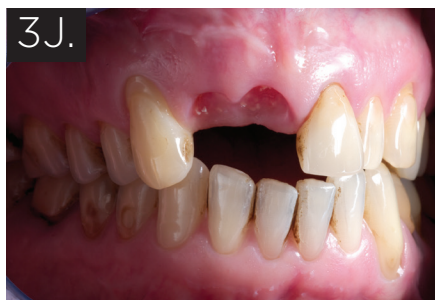**Available when you're not**



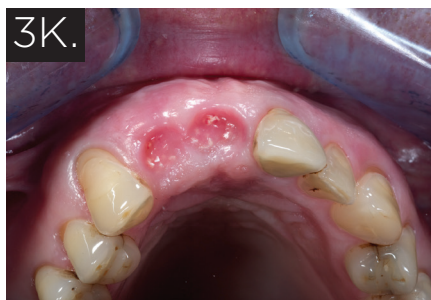**DENTAL EMERGENCY SERVICE**

1650 Yonge Street  
Toronto, Ontario M4T 2A2  
(416) 485-7121 • (416) 485-4394

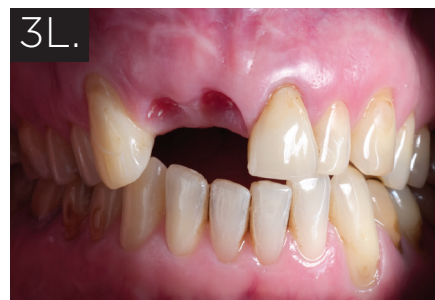



Labial view at three months with excellent soft tissue health.



Incisal view at three months with complete epithelialization and remaining non-absorbed particulate xenograft.



Labial view at five months.

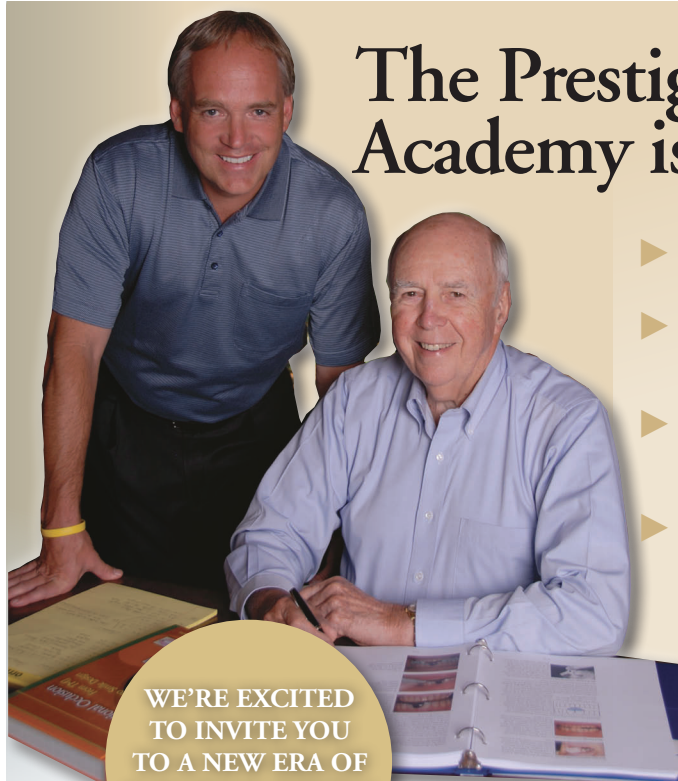
from the cancellous bone structure; this improves penetration of the surrounding tissues into the graft material.

Then chemical treatment denatures non-collagenic proteins, inactivates viruses and destroys bacteria. Further oxidative treatment denatures persisting soluble proteins and eliminates

potential antigenicity. Dehydration preserves the structural integrity of the material. Final sterilization by gamma radiation ensures sterility.

Allografts are available in different shapes from demineralized bone matrix granules to complete bone segments.

## The Prestigious Dawson Academy is Now in Canada.



WE'RE EXCITED  
TO INVITE YOU  
TO A NEW ERA OF  
CANADIAN DENTAL  
EDUCATION.

Dr. John Cranham and Dr. Peter Dawson

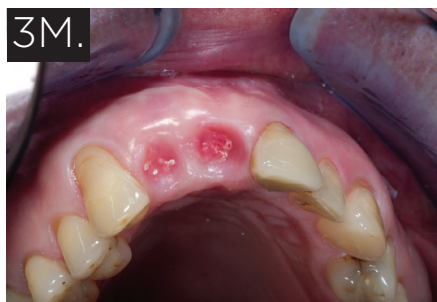
*John Cranham* *Peter Dawson*

- ▶ Proudly teaching and guiding dentists and dental lab technicians for over 35 years.
- ▶ Using proven principles and processes, we teach how to diagnose and treatment plan any case predictably and successfully.
- ▶ Find out how Complete Care and predictability can positively influence your personal and professional life balance.
- ▶ A world-class experienced faculty that have implemented and perfected these systems in their practices and provide hundreds of hours of CE training worldwide.

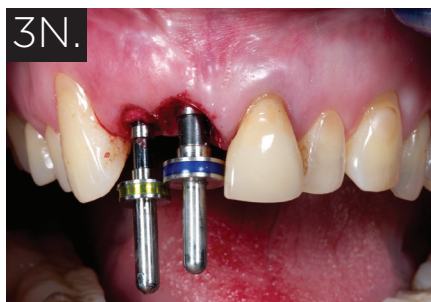THE DAWSON ACADEMY  
**CANADA**

▶ **LEARN MORE AT: [www.TheDawsonAcademy.com/Canada](http://www.TheDawsonAcademy.com/Canada)**

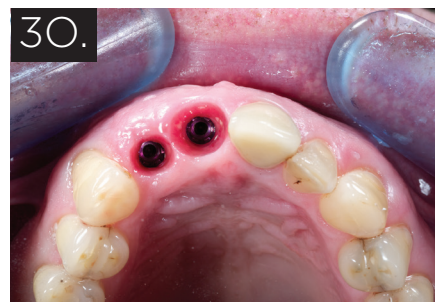



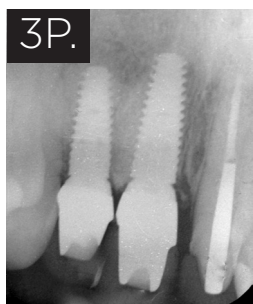
Incisal view at five months.



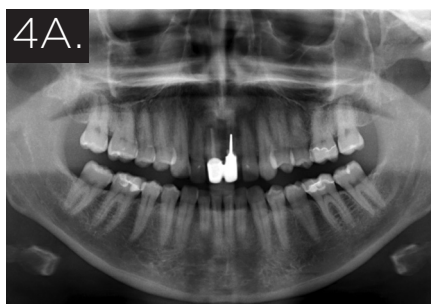
Labial view of implant positioning/direction indicators.



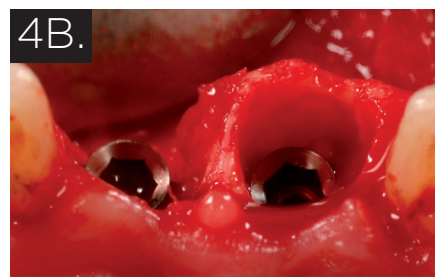Incisal view of implants with sculpted surrounding gingiva.



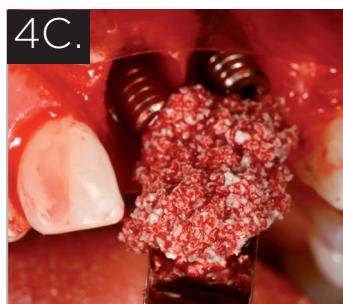Final periapical radiograph with implants in place. The above case is courtesy Dr. Ifran Ahmad, The Ridgeway Dental Surgery, UK and MIS implants.



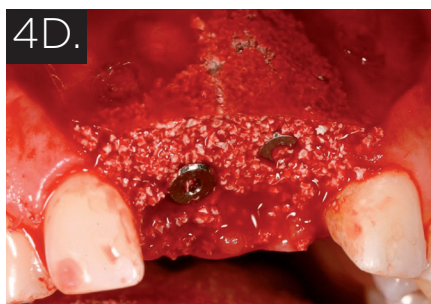Preoperative panorex. Extraction of two maxillary central incisors required.



After extraction implants are placed in the proper esthetic position.



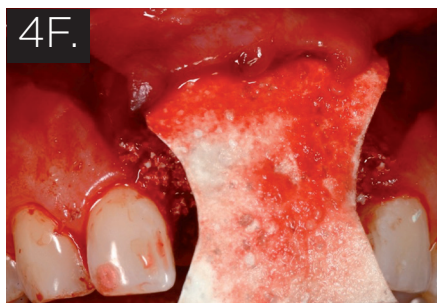Bovine xenograft particulate material (MIS 4BONE™ XBM) placed with a poly lactide membrane.



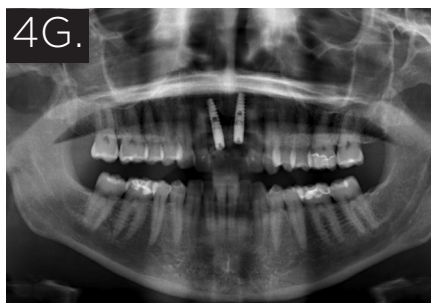Healing abutments are used for additional space maintenance.



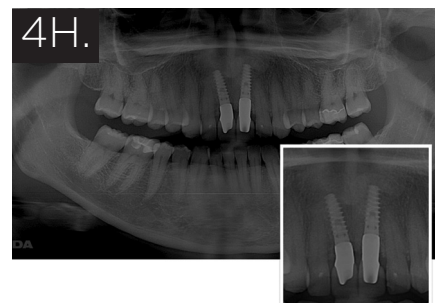Poly lactide membrane acts as a wall. Resorption is 1.5 years.



Resorbable collagen membrane is used to cover the graft.



Panorex after implant placement.



Panorex with final crowns in place six months after implant and graft surgery.

The above case is courtesy of Dr Henriette Lerner, Associate Professor University Iasi, HL-DENTCLINIC & ACADEMY, Baden-Baden, Germany and MIS Implants.

➔ on page 46



**Reverse Margin™ directs excess  
cement OUT of the tissues**



**PROTECT YOUR FOUNDATIONS TO  
Reduce Infection  
Decrease Liability  
Increase Patient Satisfaction  
Increase Success Rate  
[www.ReverseMargin.com](http://www.ReverseMargin.com)**

**core3d  
centres**  
milled by Core3D Centers  
in Canada & USA



**Diamond  
Dental Studio**

Call (905) 866-6866 or visit  
[www.DiamondDentalStudio.com](http://www.DiamondDentalStudio.com)  
for your Dental Prosthetics

A licensed provider of the Reverse Margin™

➔ from page 44

Granules can be used in socket preservation for future implant placement, ridge reconstruction for prosthetic therapy, filling osseous defects and maxillary sinus floor elevation.

Allograft bone segment blocks are a predictable and effective alternative to traditional autogenous block grafting and ridge augmentation.<sup>13</sup> When very large areas need to be grafted, a shell of autogenous bone is often used as a biologic container; this creates the necessary space for the incorporation of the particulated bone graft material. The bone cells in the autogenous bone die within a few days and then the boneplate functions as a stable, avital, slowly resorbable membrane.<sup>14</sup> Allogenic bone blocks can also be used for this shell technique as a substitute for autogenous bone. This avoids the time consuming harvesting and splitting of the autogenous bone blocks.

The space between the local bone and surrounding shell can be filled with a variety of different particulated bone grafting materials (autogenous, allogenic, xenogenic or alloplastic).

Histologic studies have shown no difference in the final stage of incorporation between allografts and autografts.<sup>15</sup>

The **xenograft** is derived from other organisms, mainly bovine. It provides long-term volume stability. Porous natural hydroxyapatite can be obtained from animal bones.

Bovine bone has a long well-documented tradition. It is deproteinized by heating to eliminate the risk of allergic reactions and disease transmission.<sup>16</sup> The removal of all proteins transforms it into biologically derived hydroxyapatite ceramic. It is characterized by well-preserved 3D natural bone structure similar to human bone. The trabecular architecture with interconnecting pores allows for optimal in-growth of new vascularity.<sup>12</sup> Guided osseous integration rather than rapid resorption leads to excellent volume stability of the graft with the formation of new bone on the highly structured bovine bone surface. The bovine bone xenograft is osteoconductive and is available in a range of volumes and particle sizes (Figs. 3 & 4).

Another option is the use of bovine collagen. Untreated collagen (which acts as a scaffold) and heat-denatured collagen (which stimulates growth) are mixed, freeze-dried and cross-linked by heat. The material is then processed into a sponge block and formed into a bullet shape for easy placement into the extraction socket. Clinical studies show stimulation of new bone at an accelerated pace<sup>17</sup> (Figs. 5, 6 & 7).

The **alloplast** is synthetically produced so there is no risk of disease transmission. The most common alloplastic materials are calcium phosphate based ceramics such as hydroxyapatite (HA) and tricalcium phosphate (TCP) (Figs. 8 & 9). Calcium phosphates are BIOACTIVE and RESORBABLE. They support attachment and proliferation of bone cells and undergo natural remodeling. There is an initial integration of the material into the surrounding bone matrix and then a



# THE MISSING LINK!



## Adding Periostat to Scaling & Root Planing (SRP) Increases Clinical Attachment Gain by 71%\*

**Periostat + SRP is proven to be more effective than SRP + Placebo, even in periodontitis patients with these complicating conditions:**

- Severe and rapidly progressing cases <sup>1-12,19</sup>
- Genotype-positive <sup>25</sup>
- Rheumatoid arthritis <sup>13</sup>
- Cardiovascular disease <sup>14-17</sup>
- Post-menopausal osteoporosis <sup>18,21,24</sup>
- Smokers <sup>7</sup>
- Diabetes <sup>22,23</sup>

**The safety profile is similar to placebo, with no rebound effect <sup>1-6</sup>**

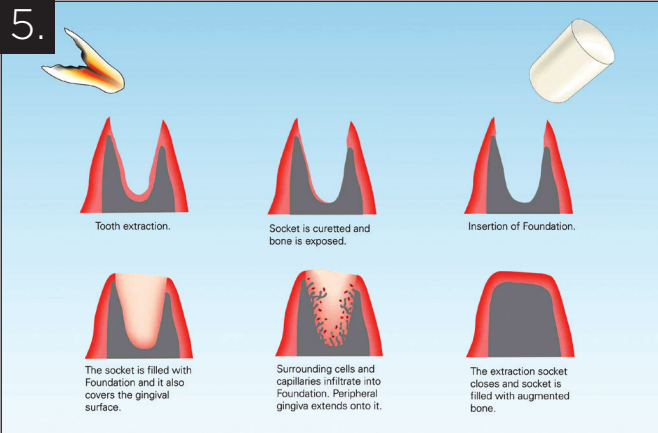
TM PERIOSTAT	
NAME / NOM _____	
ADDRESS / ADRESSE _____	
TEL _____	DATE _____
<b>Rx</b> PERIOSTAT Capsules 20 mg Quantity / Quantité <input type="checkbox"/> 60 capsules (1 mois / 1 month)	
Sig : One capsule B.I.D. to be taken 1 hour before or 2 hours after breakfast and dinner (12 hour intervals). Sig : Une capsule B.I.D. à prendre 1 heure avant ou 2 heures après le déjeuner et le dîner (12 heures d'intervalle).	
PERIOSTAT DIN 0247104 PENDOPHARM, a division of Pharmascience Inc. : 1 888 926-7653 Product Number / Numéro de produit : 5760602305	
SIGNATURE _____ LIC. # _____	
REPEAT PRESCRIPTION	1 2 3 4 5 NR
No replacement / Pas de substitution  PENDOPHARM	

For the monography, scientific references & prescription kit:  
1 888 442.7070  
[oralscience.com/periostat](http://oralscience.com/periostat)



DIN 02247104

\*JADA 146(7) <http://jada.ada.org> July 2015 p. 525-535 Table 5.



**Clinical protocol for insertion of Foundation, a collagen-based bovine xenograft (J MORITA).**

gradual degradation. HA is incompletely resorbed while TCP is completely resorbed.

HA is the inorganic base bone substance that makes up two thirds of bone. HA ceramics are chemically nearly identical to natural HA.<sup>12</sup>

TCP is a calcium phosphate ceramic that is used as a synthetic scaffold substance in dentistry and orthopedics. Both TCP and HA have blood biocompatibility and osteoconductivity without immunogenic or toxic effects. However, they possess no osteogenic or osteoinductive properties and demonstrate minimal immediate structural support.<sup>12</sup>

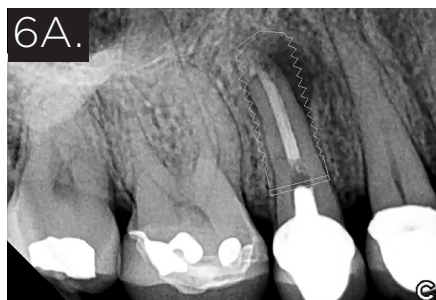
HA and TCP differ in the biologic response created at the host site. TCP is removed from the implant site as bone grows into the scaffold; HA is more permanent.

HA's slow solubility provides long term volume stability. It is also an excellent carrier of osteoinductive growth factors and osteogenic cell populations, adding to its value as a bioactive delivery vehicle.<sup>12</sup>

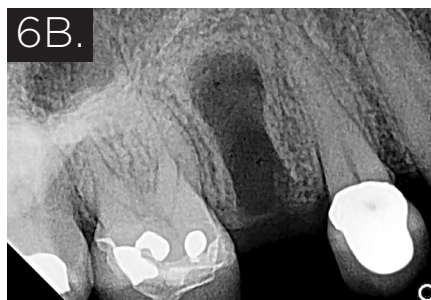An ideal bone regeneration material should be resorbed in pace with new bone formation. The basic principle of using HA and TCP in combination is a balance between the stable HA which can be found years after implantation, and the fast resorbing TCP. The ratio between the two affects the resorptive properties of the graft material. A ratio between 65:35 and 55:45 of HA to TCP has been proven particularly suitable in many studies.<sup>18</sup>

The HA portion remains integrated in the newly formed bone, while the TCP part of the product is resorbed; it is replaced by new bone which imbeds itself within the remaining HA component creating a stable scaffold.<sup>4</sup> Products with TCP alone are completely resorbed and replaced by bone within five to 15 months.<sup>4</sup>

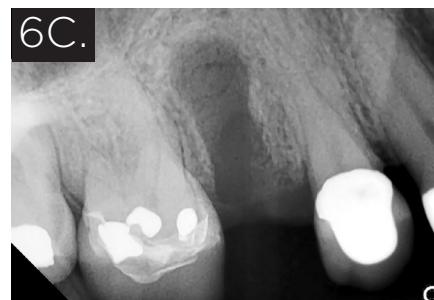Bioactive glass is another alloplastic bone substitute



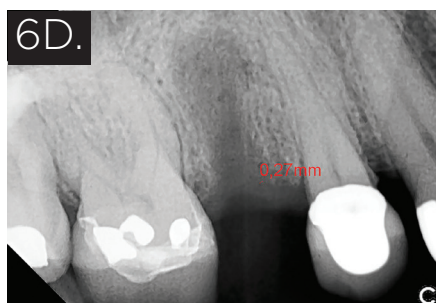Pre-extraction periapical radiograph of tooth # 15 with fractured root.



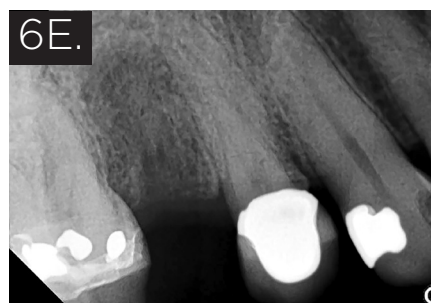Post extraction.



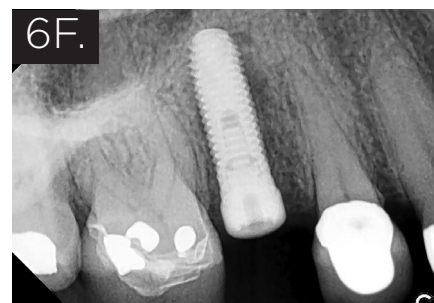
Foundation placed.



Four weeks post extraction.



Eight weeks post extraction.



Implant placed.

The above case is courtesy of Dr. Arthur Greenspoon, Montreal, Quebec and J MORITA.

material. It is used extensively in orthopedics and dentistry. It is more reactive than inert materials like HA or TCP. Intrinsic properties of bioactive glass give it the ability to promote natural bone regeneration by releasing mineral ions.<sup>19</sup> After reacting with blood it binds with bone and progressively releases silica ions. This stimulates osteoblast differentiation and proliferation.<sup>20, 21</sup> Over time, it is fully absorbed and replaced by bone. When mixed with autogenous bone graft material, it doubles natural bone regeneration.<sup>22</sup>

Different types of bone substitute materials can be combined and even hybridized to accommodate the needs of the clinical situation. Adjustment of material composition and physical characteristics allows for a wide range of resorption rates as well as physical forms such as powders, granules, pastes, blocks and even custom manufactured grafts. The selection of products allows the clinician to obtain optimal clinical outcomes.

Scientific foundations for bone grafting lead to practical clinical considerations. These are discussed below.

#### Consensus on Surgical Techniques and Materials

- The survival rates of implants placed into grafted areas are comparable with survival rates of implants placed into

pristine bone.<sup>1</sup>

- Bone quality at the recipient site determines the type of graft material to be used. Cortical bone is inferior to cancellous bone at the recipient bed. Cells within cancellous bone are responsible for at least 60 percent of the patient's bone healing capacity. The periosteum in a young, healthy patient contributes an additional 30 percent. Cells in the cortical bone are responsible for only 10 percent of bone healing. After extraction, when bone resorbs, cancellous bone shrinks relative to cortical bone. As the cancellous compartment decreases, the reservoir for osteoblasts does as well. Computerized tomography can reveal the ratio of cancellous bone to cortical at the recipient site prior to surgery. This ratio helps in the selection of the graft material as follows:

Only **cortical bone**—autograft

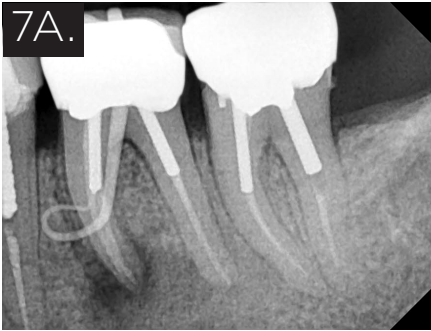
**Cortico-cancellous**—depends on predominant type

Mostly **cancellous**—everything is possible<sup>2</sup>

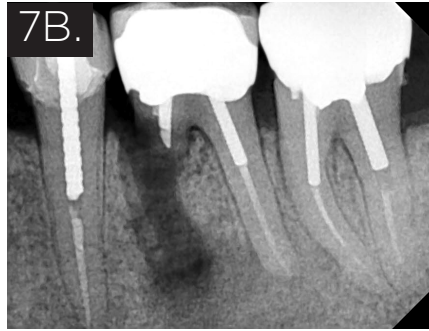
- Ridge preservation techniques are effective in limiting horizontal and vertical bone loss post extraction versus healing by blood clot alone.<sup>29</sup>

➔ on page 51

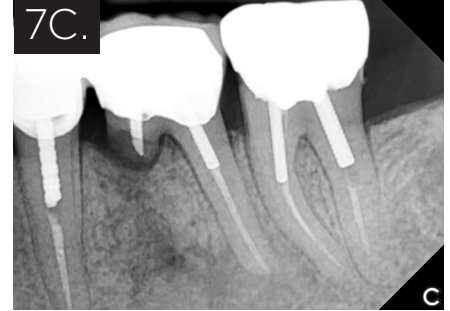




7A. 80-year-old patient with root fracture.

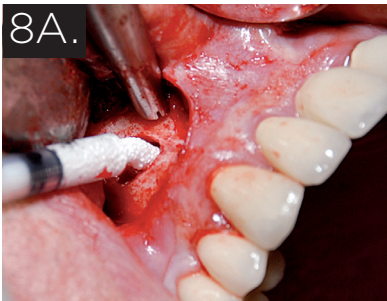


7B. After root resection.



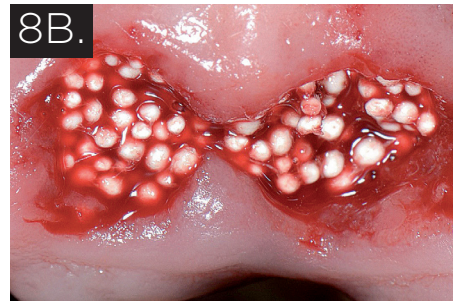7C. Six months after placement of Foundation.

The above case is courtesy of Dr. Arthur Greenspoon, Montreal, Quebec and J MORITA.



GUIDOR® *easy-graft* (SUNSTAR GUIDOR) presents a homogenous moldable mass, which is applied directly from the syringe. It is an alloplastic material, which comes in TCP-only and TCP-HA combinations.

Figures 8A & 8B courtesy of SUNSTAR.



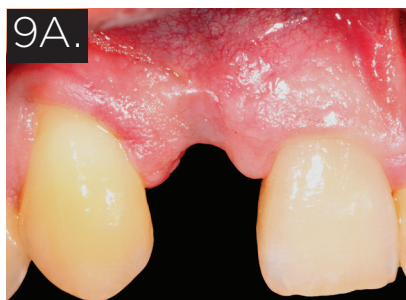Compaction of the GUIDOR® *easy-graft* causes blood to permeate the space between the granules. The material quickly hardens in contact with blood, forming a scaffold of interconnected granules, to fit the defect morphology. In larger defects, a second application can be applied immediately after the first.

- Strong evidence shows that ridge preservation significantly maintains ridge width and height. Most graft materials are effective with only slight differences between them.<sup>29</sup>
- 'External' augmentation procedures, both horizontal or vertical, on the alveolar ridge are more difficult than 'internal' augmentation procedures in areas like the maxillary sinus.<sup>1</sup>
- Augmentation of vertical alveolar ridge defects exhibit higher complication rates than those for horizontal defects.<sup>28</sup>
- For horizontal and vertical ridge augmentation procedures autogenous bone blocks result in higher gain than particulate materials. Survival rates of implants placed in horizontally and vertically augmented alveolar ridges are high.<sup>8</sup>
- Autogenous onlay bone grafting procedures are effective and predictable for the correction of **severely resorbed** edentulous ridges to allow implant placement. Survival rates are slightly lower than those of implants placed in native pristine bone.<sup>8</sup>

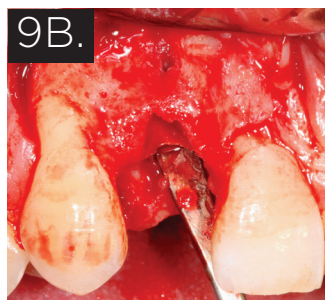
- There is a lack of long term information on the longevity of preserved ridges and the survival of the implants placed.<sup>29</sup>
- And of course:
- Poor blood supply, trauma or extensive surgery in the area can worsen the prognosis.<sup>23</sup>
  - Complications are higher in smokers.<sup>24, 25</sup>
  - General diseases affecting bone metabolism like uncontrolled diabetes, radiation to head and neck, bisphosphonate therapy are at least relative contraindications for bone augmentation.<sup>26, 27</sup>

## Conclusion

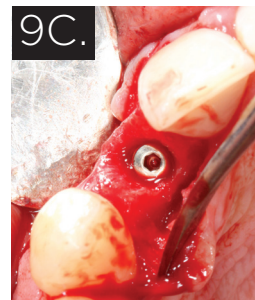The subject of bone grafts for implant procedures is complex and confusing for the surgeon, let alone the restorative dentist and patient. This article has attempted to simplify and clarify the basics. Armed with this information, the general dentist can be a better judge of the techniques and materials used. This information can prepare the clinician for counseling



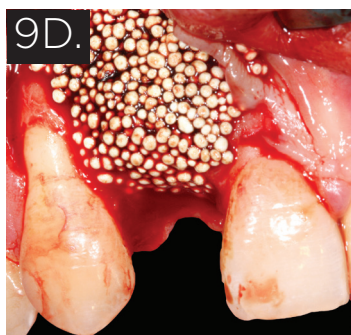
9A. Missing #12 due to accident (eight weeks after trauma).



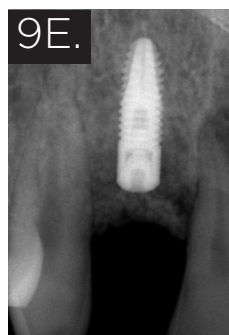
9B. Flap elevation revealed a buccal fenestration and thin buccal plate.



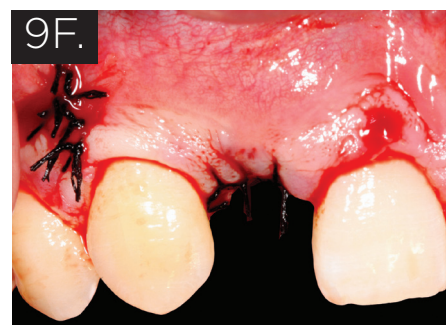
9C. Implant placed in palatal site to avoid buccal exposure of screw. The implant was set 1.5 mm below the crestal bone level.



9D. Placement of GUIDOR *easy-graft* CRYSTAL. In-situ hardening provides good stabilization.



9E. Radiograph after implant and graft placement.



9F. Flap closure.

patients on the surgical procedures to be performed at the specialist's office or be the impetus to further exploration of simple bone grafting procedures that can be done in the general practice. **OH**

Dr. Fay Goldstep has been a featured speaker in the ADA Seminar Series and has lectured at the American Dental Association, Yankee, American Academy of Cosmetic Dentistry, Academy of General Dentistry, and the Big Apple Dental conferences. She has lectured nationally and internationally on Proactive/Minimal Intervention Dentistry, Soft-Tissue Lasers, Electronic Caries Detection, Healing Dentistry and Innovations in Hygiene. She has served on the teaching faculties of the postgraduate programmes in Aesthetic Dentistry at SUNY Buffalo, University of Florida, University of Minnesota and University of Missouri-Kansas City. She is a Fellow of the American College of Dentists, International Academy for Dental-Facial Esthetics, American Society for Dental Aesthetics and the Academy of Dentistry International. Dentistry Today has listed her as one of the leaders in continuing education since 2002. She sits on the editorial board of Oral Health. Dr. Goldstep is a consultant to a number of

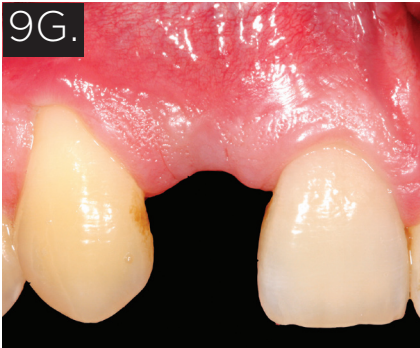dental companies and maintains a private practice in Markham, Ontario. She can be reached at [goldstep@epdot.com](mailto:goldstep@epdot.com).

Oral Health welcomes this original article.

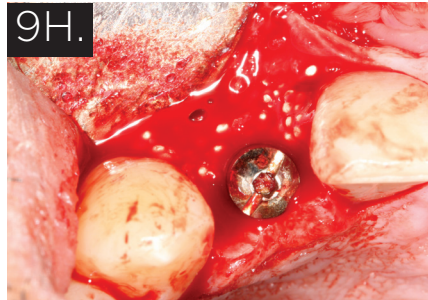
## REFERENCES

1. Klein MO, Al-Nawas B. For Which Clinical Indications In Dental Implantology Is The Use Of Bone Substitute Materials Scientifically Substantiated? *Eur J Oral Implantol* 2011; 4 (suppl): S11-S29
2. Smiler D, Soltan M. The Bone Grafting Decision Tress: A Systematic Methodology for Achieving New Bone. *Implant Dentistry* 2006; Volume 15, Number 2.
3. Wang H-M, Kiyonobu K, Neiva RF. Socket Augmentation: Rationale and Technique. *Implant Dentistry* 2004; Volume 13, Number 4.
4. Schug J, Kirste M, Huber A, Hollay HC, Troedhan A, Leventis MD. Post Extraction Alveolar Ridge Preservation: Scientific Background, Minimally Invasive Treatment Protocols and Expert Reports Using Alloplastic Biomaterials. *Sunstar GUIDOR* 2014;V 1.0.
5. Araujo M G, Liljenberg B and Lindhe J: beta-tricalcium phosphate in the early phase of socket healing: an experimental study in the dog *Clin Oral Implants Res* (2010) 21(4): 445-54.
6. Vignoletti F, Matesanz P, Rodrigo D, Figuero E, Martin C and Sanz

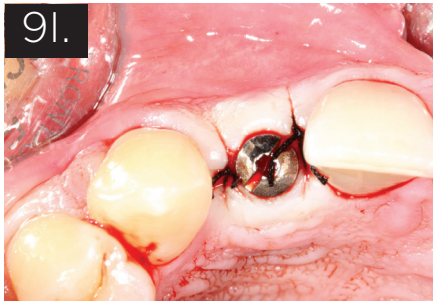
→ from page 52



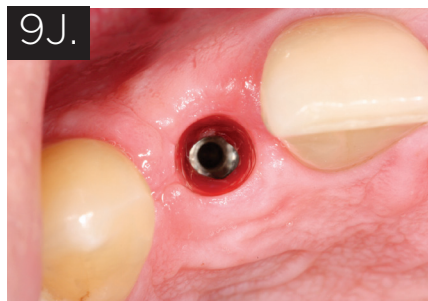
Labial view four months after implant and graft placement.



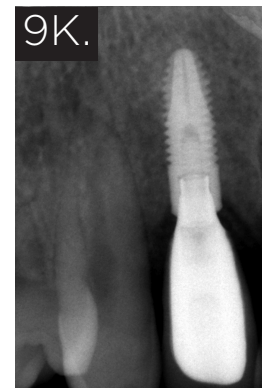
Incisal view after reopening flap (four months after grafting). Note: good hard tissue with well integrated visible granules. Partial removal of hard tissue to uncover implant screw.



9 I: Closed flap around healing cap.



Incisal view seven weeks after reopening the flap.



Periapical radiograph at two-year follow-up

The above case courtesy of Dr. Antonio Flichy, University of Valencia, Spain and SUNSTAR GUIDOR.

- M: Surgical protocols for ridge preservation after tooth extraction. A systematic review Clin Oral Implants Res (2012) 23 Suppl 5: 22-38.
7. Araujo M G, Liljenberg B and Lindhe J: Dimensional ridge alterations following tooth extraction. An experimental study in the dog J Clin Periodontol (2005) 32(2): 212-8.
  8. Jensen SS, Terheyden H. Bone Augmentation Procedures in Localized Defects in the Alveolar Ridge: Clinical Results with Different Bone Grafts and Bone-Substitute Materials. The international Journal of Oral & Maxillofacial Implants; Volume 24, Supplement 2009.
  9. Wheelless' Textbook of Orthopedics. Data Trace Internet Publishing, LLC.
  10. Rothamel et al. (2012). Clinical aspects of novel types of collagen membranes and matrices-Curent issues in soft and hard tissue augmentation. European Journal for Dental Implantologists.
  11. Laney WR (ed). Glossary of Oral and Maxillofacial Implants. Berlin: Quintessence, 2007.
  12. Kolk A, Handschel J, Drescher W, Rothamel D, Kloss F, Blessmann M, Heiland M, Wolff K-D, Smeets R. Current Trends and Future Perspectives of Bone Substitute Materials – From Space Holders to Innovative Biomaterials. Journal of Cranio-Maxillo-Facial Surgery 2012; 40: 706-718.
  13. Gomes KU, Carlini JL, Biron C, Rapoport A, Dedivitis RA. Use of allogeneic bone graft in maxillary reconstruction for installation of dental implants. J Oral Maxillofac Surg. 2008 Nov;66(11):2335-8.
  14. Etel F, et al. Theoretische Grundlagen der Knochentransplantation. In: Hieerholzer G, Zilch H; Transplantatlager und Implantatlager bei verschiedenen Operationen. Heidelberg: Springer, 1080:1-12
  15. Urist MR, Bone: Formation by autoinduction. Science 150:893, 1965.
  16. Murugan et al. (2003). Heat-deproteinated xenogeneic bone from slaughterhouse waste: Physico-chemical properties. Bull Mater Sci 26:523-528.
  17. Rasubala L et al. (2010) Healing of Human Extraction Sockets After the Use of Foundation™, University of Rochester Medical Center. Eastman Institute of Oral Health
- Remainder of references available on our website at [www.oralhealthgroup.com](http://www.oralhealthgroup.com).