

Treatment of a 65-year-old patient

Bone stability and aesthetics using an innovative implant design

DR HENRIETTE LERNER, BADEN-BADEN, GERMANY

Implant success today consists of more than just “osseointegration accomplished”. We also have to take into account the aesthetic result. The present clinical case with high aesthetic patient expectations illustrates the treatment of a partially edentulous 65-year-old female patient with grade 2 mobility in all teeth.



1 | Morse-tapered conical connection.

Introduction

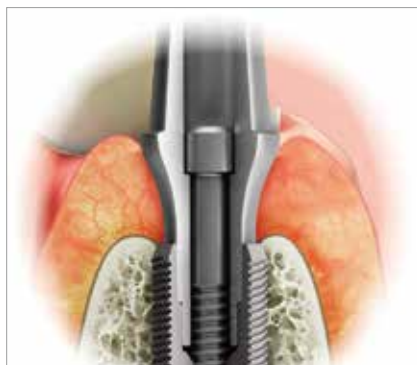The Morse-tapered conical connection (Fig. 1) has been shown to be the most stable connection available at this time. Some implant systems have started to implement it, with documented stability of the bone level (Bicon, Ankylos).

There is scientific evidence that micro-movements rather than the size of the microgap are the reason for bone loss [1]. Normally, the microgap in implant connections has been reported as being between 21 and even 60 μm , which allows for the accumulation of bacteria, local inflammation and bone loss. In a Morse-tapered conical connection, known within the aerospace industry as a “cold-welding connection”, the internal line angle between the implant and the connector is less than 0.25 degrees. The microgap is smaller (1.1–1.5 μm) than a bacterium (2–6 μm) [2].

Therefore, this connection is the most stable connection currently known and associated with the

lowest incidence of screw loosening (0.37 per cent) [3]. In addition, it has demonstrated a high level of bending stability in shear tests under 800 N at 30 degrees [4]. *Gargiulo* [5] showed in his 1980 article that the thicker the tissue above an implant > 4 mm, the less bone loss will occur after re-entry. The reason is the biologic width, which must be at least approx. 3 mm. In a thin tissue biotype (< 2 mm) the biologic width will be built at the expense of the bone.

Linkevičius [6] showed in a recent article that there will be bone loss if the tissue biotype is thin, even when using implants with platform switching. Therefore, the surgical procedure will always include changing the soft-tissue biotype with a connective-tissue graft or membranes before or during surgery. More and more studies and clinical observations show that a concave profile of the running room creates a higher and thicker volume of peri-implant tissue [7] and maintains it in the long run [8] (see Figs. 4 to 6).



2 | Innovative C-Tech implant design.



3 | Platform-switching concept.



4 | Healing abutment with concave running room.



5 | Provisional/impression abutments with a concave profile (concave running room).



6 | Final abutments with a concave profile (concave running room).

Photos 1–6: C-Tech

Based on these principles, the implant system used in the present case uses a suitable platform-switching concept (Figs. 2 and 3) and a concave profile of the running room of the provisional, healing, impression and final prosthetic parts (Figs. 4 to 6).

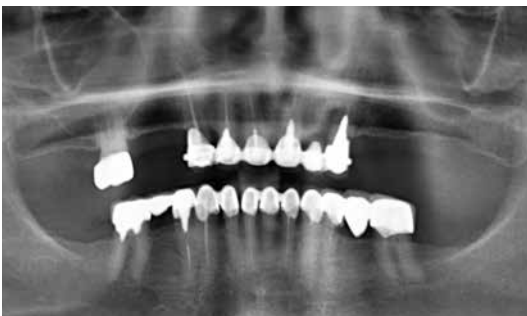Case report

A 65-year-old female patient included in a study presented with a partially edentulous situation, with all teeth having grade 2 mobility (Fig. 7). All maxillary teeth had been extracted, and extraction with immediate loading was planned for the remainder. The case was demonstrated to the pa-

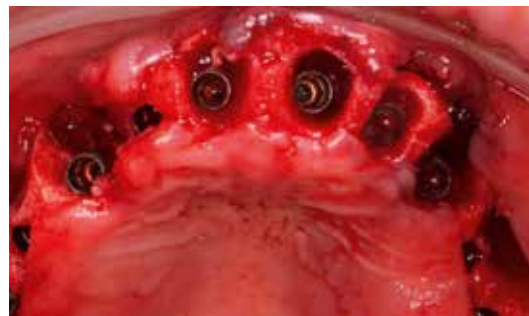tient on photos, and digital set-up was performed according to the DSD software principle. A provisional was fabricated based on the wax-up, which was inserted immediately after implant placement.

The implants were inserted in the palatal wall of the alveolus in a perfect three-dimensional position, under the bone level, at a distance of 2–4 mm from the buccal plate. All implants had a primary stability of 35 Ncm (Figs. 8 to 25).

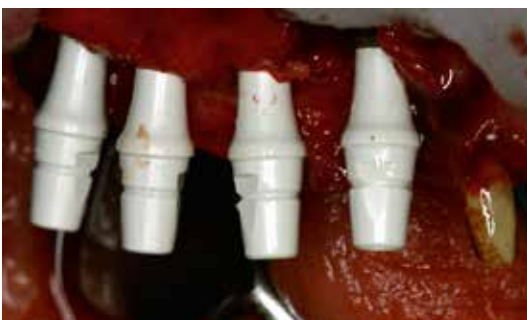There were some buccal defects that were grafted with β -TCP and HA (Maxresorb, Botiss) and Osgide (Curasan). Vertical defects were grafted with the help of the sonic weld technique (KLS Martin).




7 | Preoperative situation.



8 | Implants in place.

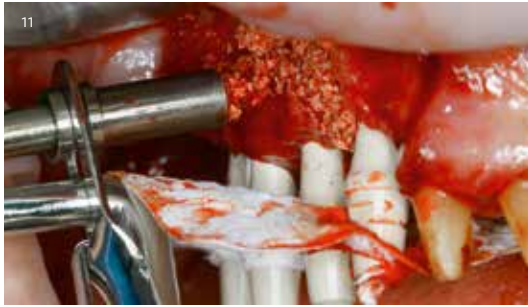

9 | Provisional abutments with 6 mm height of the concave running room.

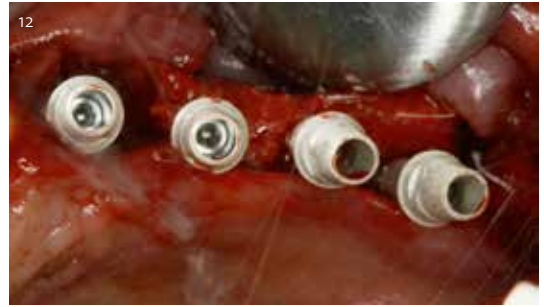

10 | The collagen membrane was perforated for overlapping the grafting buccally and palatally.

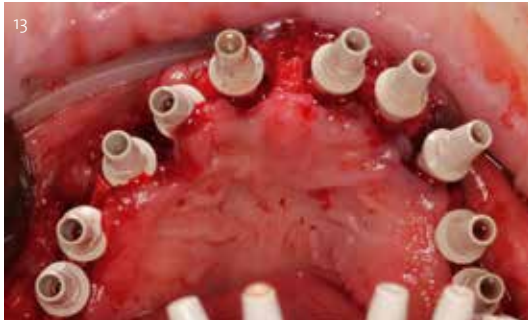
11 | The particulate material was applied.



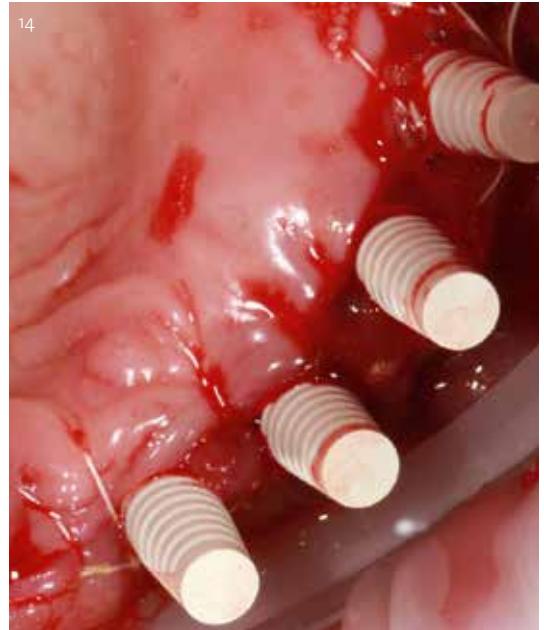
12 | The positions of the implants are the first precondition for a predictable aesthetic outcome.



13 | All implants in situ.



14 | Provisional "snap-on caps".

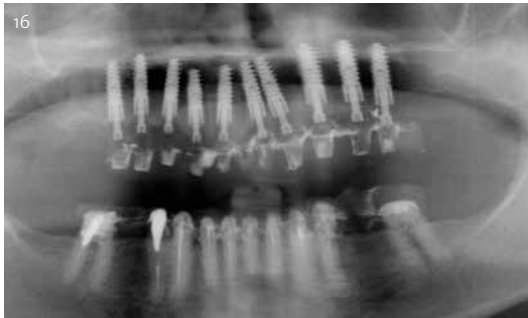

15 | The caps and the provisional abutments are made of PEEK (polyether-ether-ketone).

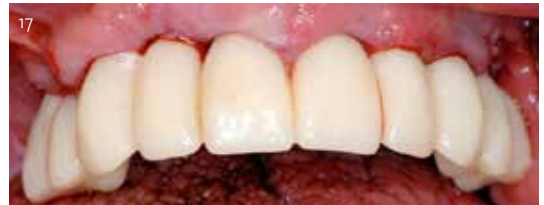Thanks to their snapping mechanism, they need very little provisional cement for fixation. They were polymerized directly in the mouth in the surgical session, into the provisional prepared in advance.



16 | After placing the implants and inserting the provisional bridge.



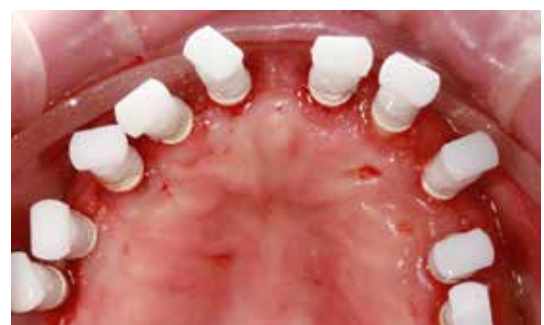17 | Provisional bridge in situ.



Discussion and conclusion

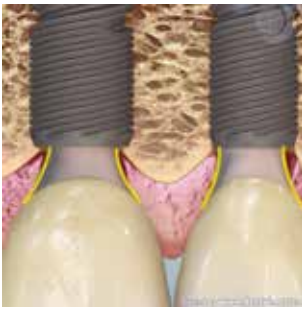
This case study uses an innovative implantological and prosthetic concept that allows the creation and stabilization of the peri-implant bone and gingival complex. This implant design and treatment concept seems to provide a better aesthetic result in situations with adjacent implants.

According to the author's daily experience, when treating the aesthetic zone, where the symmetry of the papillae should be perfect, a slightly convex profile of the individual abutment is recommended. The case study of which the present patient was a part documented 608 implants with the design

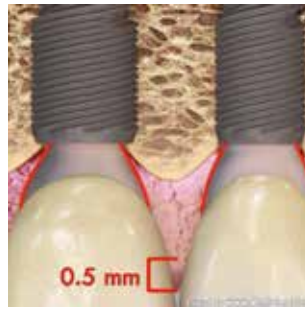


18 | After osseointegration, the same provisional abutments were used for taking impressions with the impression caps. The provisional abutments were not removed for this, reducing the number of removal of components and thereby reducing bone loss and conserving the tissues.

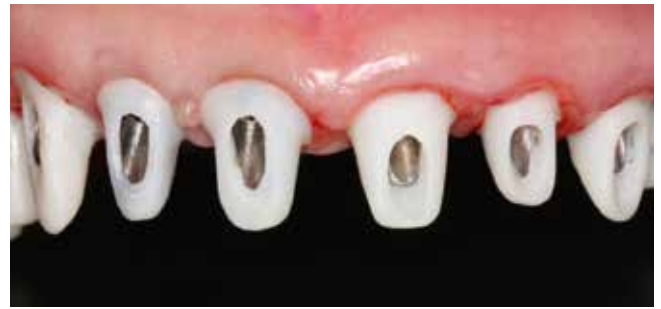described above (C-Tech, Bologna). Relevant scores were recorded for up to two years, yielding overall implant success rates near 100 per cent (99.7 per cent). In addition, highly aesthetic results were



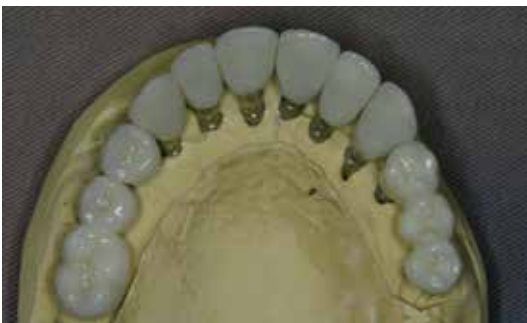19 | The platform-switching design was used to reduce bone resorption between the implants. The provisional abutment with concave running room allowed for giving the soft tissue a thicker structure around the collar.



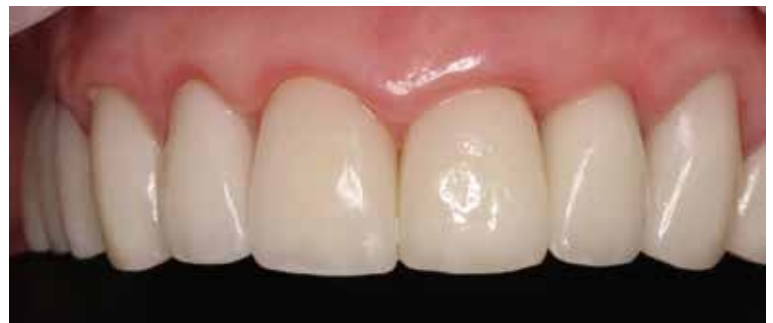20 | This final abutment was chosen to keep the concave shape the same, using the same abutment shape with the same collar height. It was prefabricated and made of titanium.



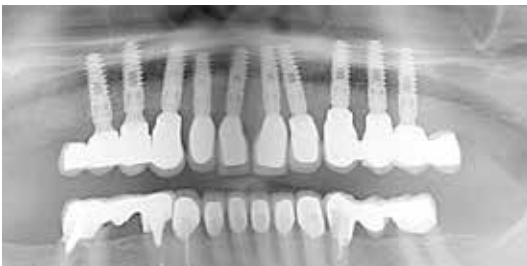21 | These custom zirconia or lithium disilicate abutments were designed such that the preparation margin was 0.5 mm below the zenith of the future marginal gingiva.



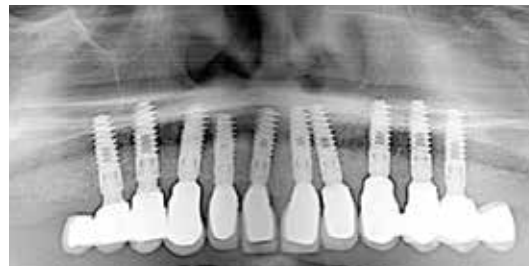22 | Dental work made of lithium disilicate ceramics (IPS e.max, Ivoclar Vivadent).



23 | Dental work in the patient's mouth. Gingival adaptation to the lithium disilicate crowns four weeks after placement.



24 | Control radiograph after delivery. Note the bone level around the implants.



25 | Control radiograph one year after delivery. The bone level is stable, with no bone loss. The bone still covers the shoulder as it had initially.

achieved (98.5 per cent), and no bone loss was detected in any case.

Within the limitations of a case study, the innovative implant and prosthetic concept design enables the practitioner to create and stabilize the peri-implant bone and gingival complex, achieving high rates of osseointegration and aesthetic success. This is the common target of any implant treatment and the answer to patients' desire.

The data recorded retrospectively in the author's practice suggest that the concept set forth offers a constructive way to implant success, including aesthetic improvement. This may encourage further re-

search including prospective studies with a higher number of cases. ■

To find the list of references visit the web (www.teamwork-media.de). Follow the link "Literaturverzeichnis" in the left sidebar.

Contact address

Dr Henriette Lerner
HL-Dentclinic
Ludwig-Wilhelm-Straße 17
76530 Baden-Baden
Germany
Phone: +49 7221 398730
info@hl-dentclinic.de